

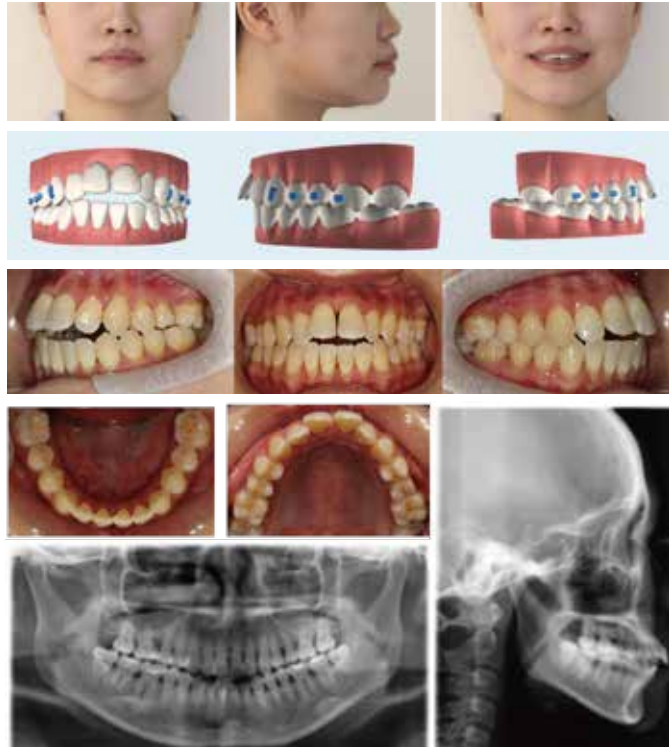Sample Case

Patient Name: Ms. Zhang Age: 20
 Complaint: Protrusion and open bite

Doctor Yantao Lee Chief Physician
 PhD in dentistry
 Executive Dean of Rizhao
 Stomatology Hospital

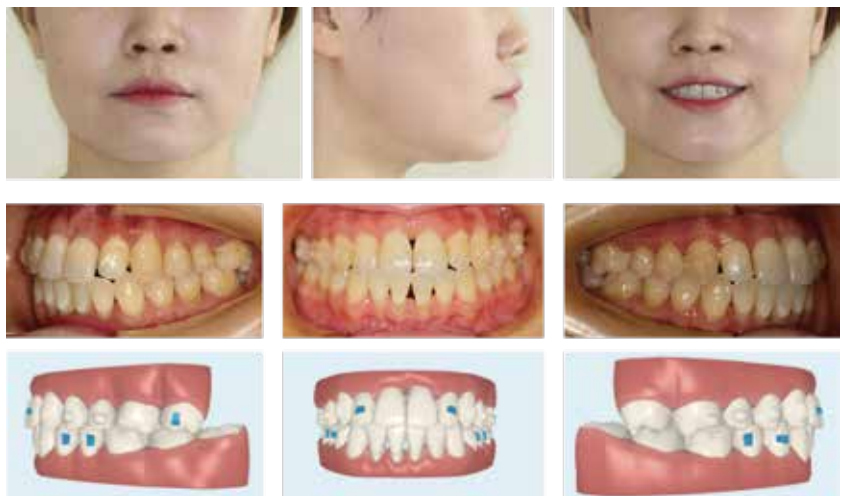Diagnosis

In the following case, the patient, a 28-year-old woman, requires maxillary correction only, complaining of upper anterior protrusion and open bite. Diagnosis of the patient shows basically neutral molar relationship, anterior large overjet, open bite, distinct black triangles existing in both upper and lower anterior teeth, and significant gingival recession.



Scheme design

Maintain the occlusal relationship of the posterior teeth. Take IPR on upper anterior teeth to relieve space, retract the anterior teeth to improve overjet and correct the anterior open bite by the pendulum effect during anterior teeth retraction. In the scheme design, the tooth movement speed shall be slowed to 0.15mm/step and 0.625mm soft films shall be better for correction.



Sample Case

Patient Name: Ms. Liu Age:33
 Complaint: Crowding and Protrusion

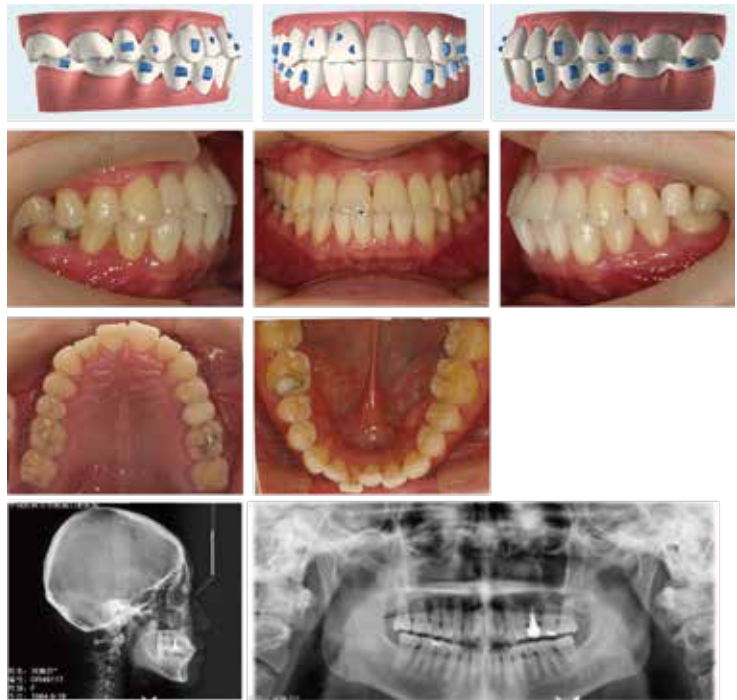
Doctor Yantao Lee Chief Physician
 PhD in dentistry
 Executive Dean of Rizhao
 Stomatology Hospital

Diagnosis

- 1、 Angle I
- 2、 Teeth protrusion
- 3、 Teeth crowding

Treatment Plan

In this case, the mild teeth protrusion is to be treated with the maxillary and mandibular molar distalization method. Due to a high Bolton index, a certain amount of IPR is required in mandibular treatment. In addition, V Pattern should be adopted in teeth movement and implant anchorage is needed in the treatment to prevent anterior anchorage loss resulting in labial inclination of the anterior teeth.



The scheme is designed into 45 steps and the basic situation of the patient after wearing all the aligners are as shown in the following figure.

Tag

The clear aligners can perfectly achieve molar distalization under the premise of sufficient retromolar space and anchorage, the problems of mild protrusion and mild crowding can be solved.

